

## Normal physiology of the pericardium

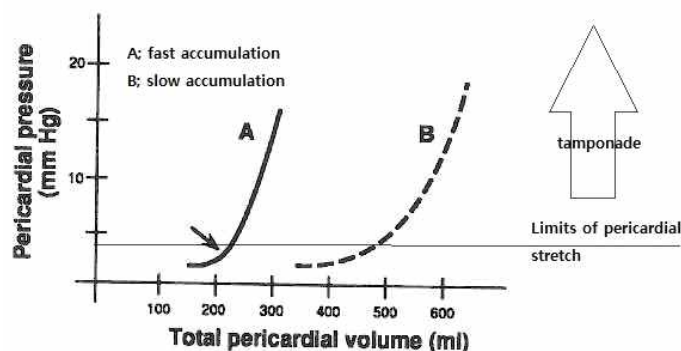
Eun Jung Cheon M.D.

Department of pediatrics

Konyang University Hospital, Daejeon, Korea

Normal pericardium is a fibroserous sac which surrounds the heart and adjoining portions of the great vessels. The inner visceral layer (epicardium) consists of a thin layer of mesothelial cells closely adherent to the surface of the heart. The parietal pericardium consists of collagenous fibrous tissue and elastic fibrils. Between the two layers lies the pericardial space, which contains approximately 10-50ml of fluid, which is an ultrafiltrate of plasma. Drainage of pericardial fluid is via right lymphatic duct and thoracic duct.

Pericardium stabilize the heart within the thoracic cavity by virtue of its ligamentous attachments, limiting the heart's motion. Also it protect the heart from mechanical trauma and infection from adjoining structures. The pericardial fluid serve as a lubricant and decreases friction of cardiac surface during systole and diastole. The major function relates to the relatively rigid and noncompliant nature of the parietal pericardium, limiting cardiac chamber distension with changes in volume and contributing to ventricular stiffness in diastole. "**Pericardial restraint**"; the compliance of the pericardium varies with the volume in the heart; initially the pericardium is supple, and can expand with minimal increases in intrapericardial pressure with cardiac filling. The volume that can be accommodated without increasing pressure in the pericardial space is known as the pericardial reserve volume 50-75mL. At higher volumes, the intrapericardial pressure rises, and impedes systemic and pulmonary venous return (Figure 1). This explains why acute increase in pericardial fluid volume lead to very high intrapericardial pressure and impedance to cardiac filling and ejection (e.g. cardiac tamponade) whereas slowly growing effusions are more well



tolerated.

Figure 1. pericardial restraint